

CASE REPORT

Severe Ulcerative Dermatitis in a Captive African Lion

I.S.Chuma¹, A.B.Matondo²

¹Tanzania National Parks, Department of Conservation Science (Veterinary Unit),
P. O. BOX 3134, Arusha, Tanzania.

²Department of Veterinary Anatomy and Pathology, College of Veterinary Medicine and Biomedical Sciences, Sokoine University of Agriculture, Morogoro, Tanzania.

E-mail: chumaidr@gmail.com

SUMMARY

Free ranging wild animals are known to be capable of co-existing with a wide range of parasites without experiencing significant health effects. Interestingly, the same parasites can cause severe health deterioration to animals under captivity. An investigation was therefore conducted following a report of a captive lion with unusual skin appearance coupled with increased fly activities. Physical and laboratory investigation revealed severe ulcerative dermatitis, moderate hematological changes and the presence of intracutaneous and gastrointestinal parasites. Furthermore, inappropriate use of antihelmintics was observed that was not protective against worm infestation. The use of parenteral ivermectin and other supportive therapy alleviated the condition. It is expected that this report will enrich the existing body of knowledge and stimulate constructive discussions among professionals managing captive wild animals for the purpose of improving animal health and welfare.

Key words: *Panthera leo*, *Simba*, *Nematodes*, *Demodex*, *Zoo*, *Allopecia*

INTRODUCTION

Wild animals in their natural habitats are sufficiently resilient and capable of co-existing with a wide range of parasites without experiencing significant health effects (Bjork *et al.*, 2000., Müller-Graf, 1995). However, these parasites that are known to depend on their living host for their survival can cause a notable health deterioration to animals under captivity (Pence and Ueckermann, 2002). The cause behind this changes in host-parasite relationships is not certainly understood. Some studies propose that animals living in close proximity to each other in captivity and the change in environment may cause a considerable stress to animals leading to the decrease in immunity and increased parasitic burden that may affect the ability of the hosts to tolerate the parasites (Borgsteede, 1996., Sulehria *et al.*, 2014).

Similar to domestic mammals, parasites affecting wild animals are grouped into ectoparasites and endoparasites. Ectoparasites inhabit mainly on the skin or outgrowths of the skin of the host organism (Hopla *et al.*, 1994) whereas endoparasites live in the bodies of their hosts including the gastrointestinal tract. Examples of ectoparasites include cutaneous larval migrans (larval stages of parasitic helminths), mites, fleas, ticks and maggots that may cause parasitic induced dermatitis among other health changes. In severely affected animals, parasitic dermatitis can have a significant adverse impact on welfare of the affected animals of various wild species (Pence and Ueckermann, 2002). Although there are relatively numerous reports related to gastrointestinal parasites of captive and free-living lion (Müller-Graf, 1995), literature on parasitic dermatitis affecting lion are rare. This report presents

clinical findings from a captive African lion (*Panthera leo*), also known as *Simba* (in

Swahili) located in a private zoo in southwestern Tanzania.

CASE HISTORY AND CLINICAL EXAMINATION RESULTS

About five (5) years old male lion, weighing approximately 170 kilograms kept in a private owned zoo located in Southern Tanzania was spotted by zoo staff having abnormal skin condition coupled with increased fly activity around the lion. The case was reported to Tanzania National Parks Veterinary Unit (Western zone) for medical attention. Main complaints were hair loss (alopecia) and ulcers on the skin distributed around the dorsal and lateral parts of the head, neck, shoulders, as well as fore and hind limbs. The condition persisted for more than a week. Further inquiry revealed that the lion is usually fed 20 kilogram (kg) of beef or goat meat twice a week. Deworming was routinely done locally by zoo care takers who provided four (4) oral Ascaten-P® tablets once every three months. Regular cleaning of the surroundings including the shelter was done regularly including periodic use of hot water to kill parasites that hide in the wall and floor crevices.

Observations at a distance

Upon arrival at the zoo, the lion was examined at a distance while in its cage and found to have fairly good body condition score of 5 assessed using the method described previously (Daigle *et al.*, 2015). Briefly the condition was assessed on a scale of 1 to 9 where 1 is for very poor or the thinnest body condition with ribs clearly visible, no palpable fat, lumbar vertebrae and wings of ilea can easily be palpable. On the other hand, condition score 9 represent an obese lion with ribs covered with heavy fat tissues, and shows

face and waist distention. Demeanor and gait were considered normal and the lion responded well to the sight, smell and sound stimuli. The animal was alert, moved around though preferred to hide in presence of people and tried to frighten them when approached. The skin lesions were clearly visible and open wounds with wet and matted hairs were visible on the affected sites. Traces of hair were observed on the ground and some were spotted hanging around on protruding metal cage bars and the supporting iron poles inside the cage.

Chemical immobilization and closer examination

The lion was immobilized using a cocktail of 120mg of Zolazepam-Tiletamine (Zoletil 100®) and 2mg of Medetomidine Hydrochloride (total doses). The projection system used was Dan-Inject system with 3ml plastic darts affixed with (2 X 40mm) collared needles (Dan-Inject, Denmark). The dart gun was set at pressure of 2 bars and the animal was darted at a distance of about 5 metres from the service door on the right side of the lion. The dart penetrated into the right *quadriceps femoris* muscles. The total time from darting to total anaesthesia was 5 minutes.

Closer examination revealed alopecic skin lesions with moist matted hairs sticking on the affected parts (Figure 1). The lesions had raised margins with pink to red centres some of which were open and oozing fresh blood. There were patches of hair loss (alopecia) on the affected parts (Figure 1, Pannel 4). Distribution of the alopecic patches was almost all over the body although the neck and shoulders were mostly affected compared to other parts (Figure 1).

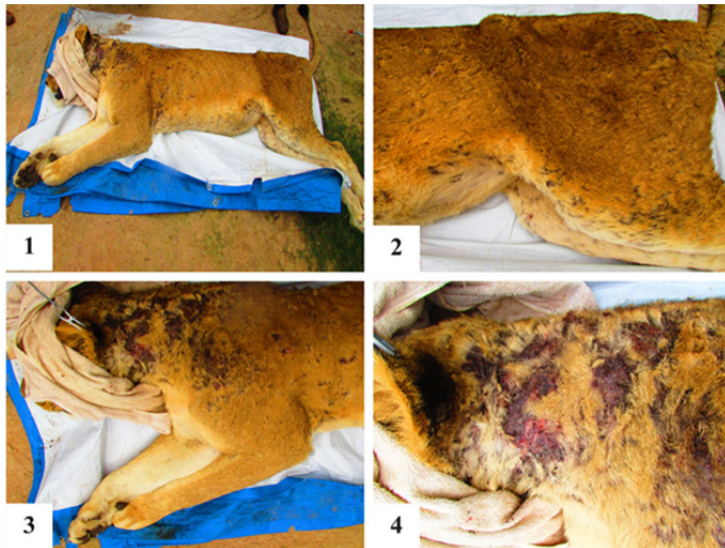


Figure 1. Ulcerative and alopecic skin lesions: Panel 1: Overview of the lesion distribution on the whole animal body. Panel 2-4: Closer view indicate severe lesion on the hindquarters, neck and shoulder regions,

Sample collection, treatment and laboratory findings

Ethylenediaminetetraacetic acid (EDTA) Blood, impression smears of the wound, fecal samples and skin scrapings were collected for Laboratory analysis. The animal was then treated with 40mg of a 1% Ivermectin solution (Ivofarm Super®, Congqing-Fantong Pharmaceutical Co. Ltd, China) and 10 milliliter of multivitamin (Eagle Vet Tech Co. Ltd, Korea), administered subcutaneously and intramuscularly respectively. In addition, the affected areas were cleaned with Dettol® solution (Soaps and Chemicals Industrial & Trading Co., Sharjah, United Arab Emirates) and sprayed with 3.58% w/w Alamycin® aerosol (Norbrook Laboratories Ltd, Northern Ireland). The

animal was then monitored until full recovery from anesthesia. Samples were packed in a box containing ice packs and transported to the laboratory for analysis. With exception of blood samples which was analyzed on arrival, all other samples were analysed on the next day.

Examination of skin scrapings and EDTA blood.

Analysis of EDTA blood was done using automated hematological analyser (MS4-5 Vet, MS Laboratories) (Table 1). Small amount of skin scrapings was added either in a drop of distilled water or 10% of potassium hydroxide and spread with pipette tip before the cover slip was applied

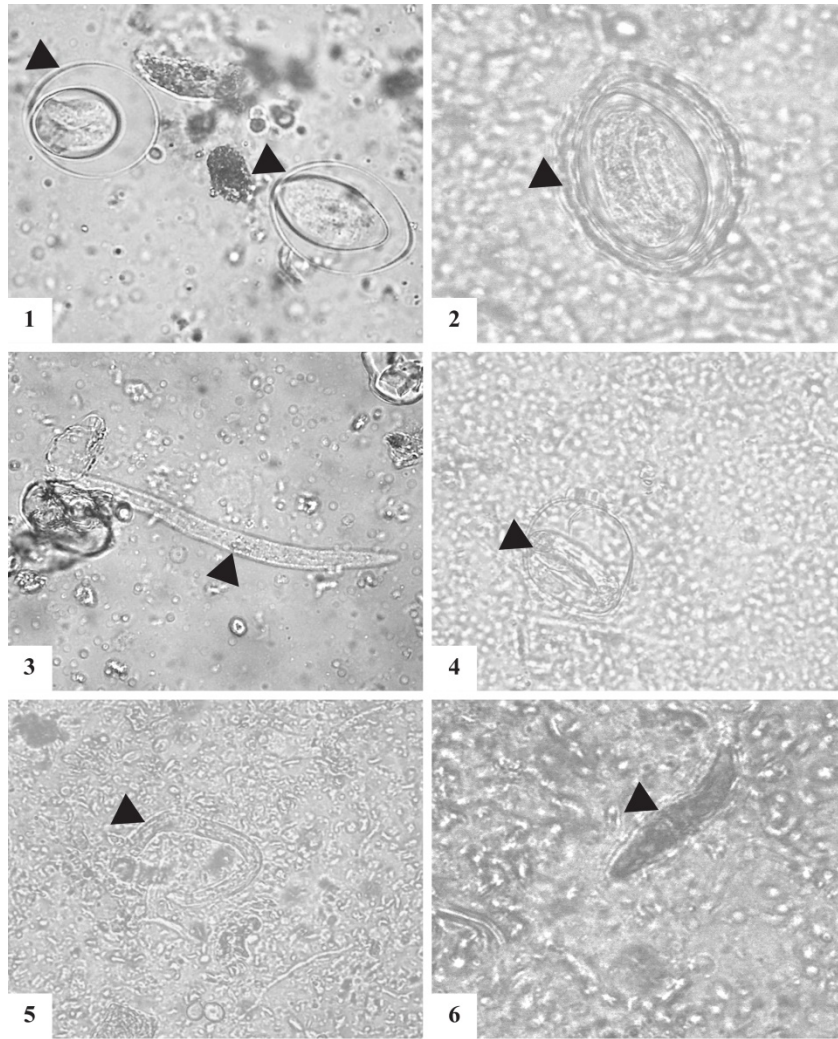


Figure 2. Skin parasites: Panel 1-2: Unidentified intermediate stages of parasites recovered from skin scrapings that are suspected to be larval stages of *Demodex spp*; Panel 3: Parasites resembling Nematode larvae; Panel 3-5: Unidentified Larvae stages of worms resembling those of Strongyloid larvae (panel 3) and hookworms (panel 4-5), Panel 6: Adult *Demodex spp*

Wet preparations of skin scrapings were examined under light microscope (Olympus BH2, Olympus), mounted with a charge coupled device (CCD) camera (Moticam Pro 205A, Motic) for imaging. Microscopy revealed different types of cutaneous

parasites including those resembling the developmental stages of worms and adult cutaneous mites (Figure 2). Hematological analysis revealed moderate increase in mononuclear leukocytes compared to known physiological levels (Table 1)

Table 1. Haematological parameters analysis results compared to published reference

Erythrocytic Parameters	Results	Reference (Hawkey and Hart, 1986)	and	Leucocytic Parameters	Results	Reference* (Hawkey and Hart, 1986)
Erythrocytes (x 10 ⁶ /μL)	11.5	6.4-9.3		WBC counts (x10 ⁹ /L)	15.58	7.9-14.1
Haematocrit (%)	59.9	31-47		Lymphocytes (%)	38.6	6-13
Haemoglobin (g/dL)	16.1	11.5-15.6		Monocytes (%)	7.8	0-4
MCV(fL)	52.1	45-59		Neutrophils (%)	52.3	63-91
MCH (pg)	14.0	15.3-19.0		Eosinophils (%)	1.0	0-5
MCHC (%)	26.8	30.8-36.5		Basophils (%)	0.3	0-1

*Reference range for captive African lion (*Panthera leo*), WBC: White Blood Cell counts, μL: microlitre, dL: desilitre, pg: picogram, MVC: Mean corpuscular volume, MCH: Mean corpuscular hemoglobin, MCHC: Mean corpuscular hemoglobin concentration

In addition to skin scrappings, wet preparations of faecal samples and giemsa stained EDTA blood smears, Periodic acid-Schiff stained wound impression smears and skin scrappings were also examined for gastrointestinal parasites, haemoparasites and cutaneous fungi

respectively. Nematode, Cestode eggs and adult worms were observed in faecal samples. However, neither fungi nor haemoparasites were found in impression smears and EDTA blood smears (data not shown).

DISCUSSION

This report present clinical findings of a captive lion with severe ulcerative dermatitis. Analysis of blood, skin scrappings and impression smears did not reveal presence of haemoparasites and fungal infection, suggesting that other aetiologies are involved for the observed skin lesions. Examination of wet preparations of skin samples, revealed different types of cutaneous parasites including those that resemble intermediate stages of *Demodex* (Figure 2, panel 1-2), *Strongyloides* (Figure 2, panel 3), *Ancylosma* and *Uncinaria* larvae (Figure 2, panel 4-5) and adult *Demodex* (Figure 2, panel 6) although the definitive identity of the parasites could not be immediately reached.

Demodicosis is known to be associated with pruritus and dermatitis in domestic feline species (Beale, 2012). Interestingly, results reported elsewhere demonstrated presence of *Demodex* parasites in free ranging lion with no clinical significance (Bjork *et al.*, 2000) suggesting that either captive environment, presence of other parasites or other factors are required for severe and a notable ulcerative dermatitis to occur. The larvae stages of *Strongyloides* and hookworms (*Uncinaria* and *Ancylostoma*) are closely similar but can be differentiated by their relative size. *Strongyloides* larvae are relatively larger, with short buccal cavity and forked tail while Hookworms are relatively smaller with long buccal cavity and pointed tail (Chu *et al.*, 2013., Viney and Lok, 2007). Based on morphology it is more likely that

the larval stages recovered from the skin scrapings are hookworm larvae due to the absence of forked tail (Figure 2, panel 3-5). Other rhabditiform larvae such as *Pelodera strongyloides* which are usually found in wet soiled environment can also cause pruritus and dermatitis in animals. However, the lesions caused by *Pelodera* are usually prominent in the abdominal region at the site of entry where there is contact with wet environments (Tanaka *et al.*, 2004). On the contrary, the observed lesions in the current case were prominent on the neck and shoulder regions (Figure 1).

In addition, other likely cause of parasitic dermatitis is the presence of cutaneous larval stages of spirometra known as spargana. *Spirometra* are known to reside in the intestines of wild carnivores (Kavana *et al.*, 2015., Müller-Graf, 1995). The larvae are capable of infecting their prospective host through consumption of meat of other animals infected with plerocercoids that subsequently develop into the second host and become encysted and cause skin lesions known as sparganosis (Drake *et al.*, 2008). Like other carnivores, lions are likely to be infected with plerocercoid larvae through consumption of meat of other animals infected with plerocercoids. However, the collected skin scrapings are unlikely to include deep cutaneous parasites lodging in the subcutaneous tissues such as spargana (Drake *et al.*, 2008).

Furthermore, the observed cutaneous larval stages of worms could be related to gastrointestinal helminths living in the same animals or other animals living in the same environment (Bowman *et al.*, 2010). Parasitic nematodes, cestode and their respective eggs were identified in faecal samples (data not shown). The helminths eggs and parasites were similar to previously published findings in lion (Bjork *et al.*, 2000). The presence of these helminths is attributed to low dosage of antihelmintic drug provided during routine

deworming using Ascaten P® below the recommended dose of Ascaten P® tablets described previously (Muhairwa *et al.*, 2013).

In addition, the lack of significant systemic disease associated with the presence of gastrointestinal helminths was not surprising. This is due to the fact that similar types of worms have been previously reported in free ranging lion without any noticeable health effects (Bjork *et al.*, 2000).

Parasitic dermatitis and pruritus are closely associated with the later mostly exhibited by the animal through scratching against hard objects and ultimately resulting into alopecia, ulceration and inflammation of the skin (Figure 1). Despite of the absence of clear increase in eosinophils, one of the common features in parasitic dermatitis, is the moderate increase in mononuclear leukocytes compared to known physiological levels (Table 1)(Hawkey and Hart, 1986). This hematological changes indicates presence of chronic inflammatory reactions. However, the definitive reasons for the observed changes in hematological parameters are not currently established.

Finally, Post-intervention follow up of the case appreciated full recovery of the affected lion within the period of three weeks, suggesting that the treatment against parasites using ivermectin and supportive medication were effective in agreement with other observations elsewhere (Campbell, 1985). Nonetheless the possibility of spontaneous self recovery cannot be completely ruled out. It is expected that this report, which put forward experience gained during the management of the encountered case will have a positive contribution to knowledge and stimulate a constructive discussion among professionals for the purpose of improving animal health and welfare.

ACKNOWLEDGMENTS

The study was successful with assistance of Mr. Zemu Mbilu in the course of sample processing, Support staff of Serengeti National Parks, and Staffs at the private zoo during samples collection

REFERENCES

- Beale K. Feline demodicosis: a consideration in the itchy or overgrooming cat. *J Feline Med Surgery*, 14: 209-213, 2012.
- Bjork KE, Averbeck GA, Stromberg BE. Parasites and parasite stages of free-ranging wild lions (*Panthera leo*) of northern Tanzania. *J Zoo Wildl Med*, 31: 56-62, 2000.
- Borgsteede F. The effect of parasites on wildlife. *Vet Q*, 18: 138-140, 1996.
- Bowman D, Montgomery S, Zajac A, Eberhard M, Kazacos K. Hookworms of dogs and cats as agents of cutaneous larva migrans. *Trends in parasitology*, 26: 162-167, 2010.
- Campbell W. Ivermectin: an update. *Parasitol Today*, 1: 10-16, 1985.
- Chu S, Myers SL, Wagner B, Snead EC. Hookworm dermatitis due to *Uncinaria stenocephala* in a dog from Saskatchewan. *Can Vet J*, 54: 743, 2013.
- Daigle C, Brown JL, Carlstead K, Pukazhenthhi B, Freeman E, Snider R. Multi-institutional survey of social, management, husbandry and environmental factors for the SSP African lion *Panthera leo* population: examining the effects of a breeding moratorium in relation to reproductive success. *Int Zoo Yearb*, 49: 198-213, 2015.
- Drake DA, Carreno AD, Blagburn BL, Little SE, West MD, Hendrix CM, Johnson CM. Proliferative sparganosis in a dog. *J Am Vet Med Assoc*, 233: 1756-1760, 2008.
- Hawkey C, Hart M. Haematological reference values for adult pumas, lions, tigers, leopards, jaguars and cheetahs. *Res Vet Sci*, 41: 268-269, 1986.
- Hopla C, Durden L, Keirans J. Ectoparasites and classification. *Rev Sci Tech*, 13: 985-1034, 1994.
- Kavana N, Kassuku A, Kasanga C. Prevalence of *Spirometra* species and other gastrointestinal helminths in wild lions (*Panthera leo*) in Tarangire National Park, northern Tanzania. *Int J Microbiol Immunol Res*, 4: 10-14, 2015.
- Muhairwa A, Musoke K, Msoffe P, Mshamu S, Kassuku A. Clinical and hematological trends in *Ancylostoma caninum* infected puppies fed different levels of dietary protein. *Research Opinions in Animal and Veterinary Sciences*, 3: 73-79, 2013.
- Müller-Graf CD. A coprological survey of intestinal parasites of wild lions (*Panthera leo*) in the Serengeti and the Ngorongoro Crater, Tanzania, East Africa. *J Parasitol*: 812-814, 1995.
- Pence D, Ueckermann E. Sarcoptic mange in wildlife. *Rev Sci Tech*, 21: 385-398, 2002.
- Sulehria AQK, Moqem G, Mustafa YS. Prevalence of Endoparasites in African Lion–*Panthera leo*. *Biologia (Pakistan)*, 60: 211-218, 2014.
- Tanaka A, Kinoshita M, Tanaka T, Iwanaga Y, Kagei N, Hide M. *Pelodera strongyloides* infestation presenting as pruritic dermatitis. *J Am Acad Dermatol*, 51: S181-184, 2004.
- Viney ME, Lok JB. *Strongyloides* spp. *WormBook: the online review of C. elegans Biology*: 1-15, 2007.