

Sarcoptic mange in yellow baboons and red colobus monkeys in areas with high wildlife-human interactions: Implications for wildlife management

I.S.Chuma¹, A.B.Matondo²

¹Tanzania National Parks, Department of Conservation Science (Veterinary Unit), P. O. BOX 3134, Arusha, Tanzania.

²Department of Veterinary Anatomy and Pathology, College of Veterinary Medicine and Biomedical Sciences, Sokoine University of Agriculture, Morogoro, Tanzania.

E-mail: chumaidr@gmail.com

SUMMARY

Sarcoptic mange is a parasitic and zoonotic diseases affecting skin of different mammalian species including non-human primates. The disease is caused by parasite of the genus *Sarcoptes*. In severe cases the disease has been reported to cause mortalities in mountain gorillas. This communication describes result of the investigated incidents of abnormal skin conditions reported at Saadani and Jozani-Chwaka Bay National Parks involving yellow baboons and Zanzibar red colobus monkeys respectively. Investigation results revealed localized areas of pustular dermatitis, alopecia, and scaling in the affected animals. Microscopy of skin scrapings revealed presence of *Sarcoptes scabiae* in all samples. Furthermore, the incidents in the two different parks appeared almost concurrently and a follow up to all sampled animals confirmed self-full recovery of all affected animals approximately after three months with no medical interventions. Further investigations are required to establish actual factors leading to the occurrence and regression of the observed parasitic skin condition. In addition, the occurrence of the disease in endangered red colobus monkeys call for a closer monitoring for a potentially more severe health and ecological consequences. Finally, although the disease necessitated medical interventions in Ugandan mountain gorilla, the same approach may not be necessarily applicable to other primate species.

Key words: *colobus, monkeys, baboon, sarcoptes, mange*

INTRODUCTION

Sarcoptic mange is a zoonotic and contagious inflammatory skin disease caused by *Sarcoptes scabiei* mites (Mackenstedt *et al.*, 2015). The parasites are considered to be host-specific but one species of *Sarcoptes* can cause disease in more than one animal species including cross transmission between human and non-human primates (Kalema-Zikusoka *et al.*, 2002., Mackenstedt *et al.*, 2015). In severely affected non-human primates, the disease is capable of causing mortalities (Bernstein and Didier, 2009., Kalema-Zikusoka *et al.*, 2002). The transmission of

parasites to non-human primates is considered to be higher at areas with higher human activities such as tourist attraction sites (Kalema-Zikusoka *et al.*, 2002). Similarly, the risk of the disease associated with *Sarcoptes scabiae* is considered to be higher when the environment is favourable for parasitic survival and reproduction (Sokolova *et al.*, 1989). Despite the fact that the environmental conditions and intensity of anthropogenic activities vary with season, there is no clear and sufficient evidences suggesting seasonal occurrence of

sarcoptic mange in non-human primates. Furthermore, severe untreated cases of some Sarcoptic mange may lead to mortalities (Kalema-Zikusoka *et al.*, 2002., Pence and Ueckermann, 2002).

MATERIALS AND METHODS

During the period between late June and July, Saadani yellow baboons living in Saadani National Park headquarters close to the Saadani village were spotted to have abnormal skin appearances and increasingly scratching behavior and subsequently reported to the Veterinary unit of Serengeti national park for investigations. Similar types of observations were reported from Jozani-Chwaka Bay National Park involving Zanzibar red colobus monkeys approximately during the same period. Skin scrapings were collected after visiting the parks and immobilization of the affected animals using ketamine-

This study describes results of investigations conducted following reports on the appearance of abnormal skin conditions affecting Zanzibar red colobus monkeys (*Ptilocolobus kirkii*) and Saadani yellow baboons (*Papio anubis*)

medetomidine combination at the dose rate of 8mg/Kg and 0.07 Mg/Kg body weight, respectively and reversed with atipamezole antidote at the ratio of 1:1 to that of medetomidine. Immobilization lasted for 50-60 minutes. Microscopy and imaging of wet mount was done using light microscope (Olympus BH2, Olympus), mounted with a charge coupled device (CCD) camera (Moticam Pro 205A, Motic) respectively. Re-sampling was done three months after the first examination to investigate whether the condition persisted in the previously reported animals or in other animals in the vicinity.

RESULTS

During physical clinical examination, both Colobus monkeys (n=6) and Yellow baboons (n=2) revealed pustular skin lesions. The lesions were much more severe in Yellow baboons, therefore baboon were treated with topical

antibiotics. No any other medications were provided. In addition to pustular dermatitis, the animals revealed patchy to generalized alopecia, and scaling in affected sites. All the affected animals were active before and after immobilization.

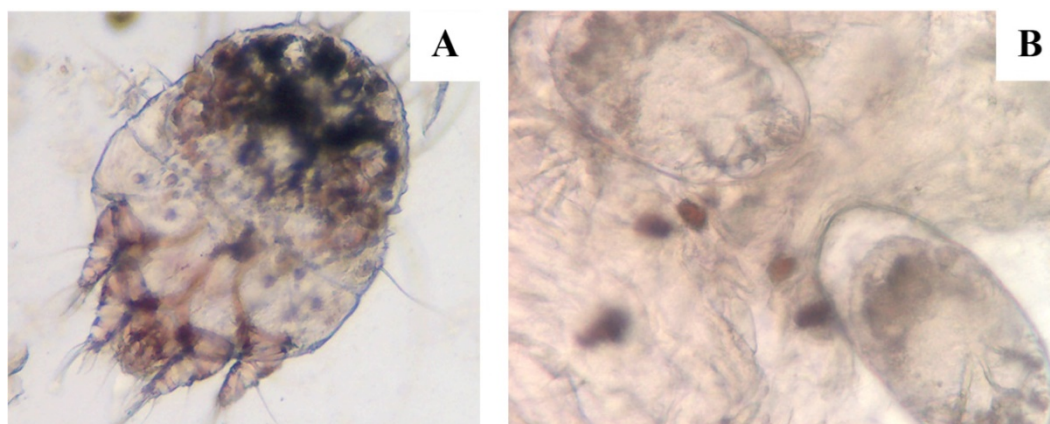


Figure 1. Adult (A) and eggs (B) of *Sarcoptes scabiea* recovered from skin scaraping of Zanzibar red colobus monkeys (n=6) and Saadani yellow baboons (n=2).

Laboratory analysis of skin scraping samples from baboons and monkeys showed multiple *Sarcoptes* mites identified with their characteristic circular wide bodies, and short legs (Figure 1 A). Some samples revealed presence of mite eggs at different

developmental stages (Figure 1 B). Periodic and Schiff (PAS) staining of dried wet skin scrapings revealed no PAS positive fungal hyphae. Examination and re-sampling of the affected animals revealed full recovery and no parasite was recovered in the samples

DISCUSSION

In the absence of other infectious agents characterized by pruritus and scaling of skin, the identified *Sarcoptes* can be confirmed as the cause of abnormal skin condition observed in baboons and monkeys (Figure 1A-B). This is the first report describing sarcoptic mange (Figure 1) in Saadani yellow baboons and Zanzibar red colobus monkeys. The latter being among the endangered species (Mittermeier *et al.*, 2009) and that are endemic to Zanzibar. The occurrence of the disease at the same period in two different geographical locations suggests seasonal pattern. However, being the first documented case, there is no sufficient evidence to support this supposition.

Closer follow up study will be necessary to confirm or refute the seasonality of the disease. However, the geographical locations of the affected animals have closely similar climatic conditions. Both Saadani National Park which is found at the central north-eastern coast of the Indian ocean and Jozani-Chwaka Bay National Park in Unguja on the Zanzibar Island all share almost similar climatic conditions and are usually wet and humid throughout the year, the conditions which are favourable for *sarcoptes* survival and reproduction (Sokolova *et al.*, 1989) as well as other pathogens (Hill, 1953). Therefore it is likely that environmental factor contributed to the concurrent occurrence of the disease in the two sites.

Nonetheless, location where baboons were affected in Saadani was closer to residential areas. Similarly, Jozani Chwaka Bay National park is among the tourist attraction

site in Zanzibar. The close proximity of the affected animals to areas with higher human activities increases the potential of cross-transmission of the parasites from human to baboons, monkeys and vice versa through environmental contaminations based on the ability of the parasite to crossover between human and other mammals (Bandi and Saikumar, 2013). While human factors are likely to be involved in the development of sarcoptic mange based on experiences gained from similar conditions in mountain gorilla (Kalema-Zikusoka *et al.*, 2002), the possibility of other multifactor involvements cannot be ruled out. The actual factors and events leading to the occurrence and regression of the disease observed in both baboons and monkeys remain to be subjects of further investigations.

Interestingly, there was no recorded mortality in baboon or red colobus monkeys contrary to previously reported similar condition in other non-human primate species (Kalema-Zikusoka *et al.*, 2002). In addition, yellow baboons showed relatively more severe pustular lesions compared to red colobus monkeys. The cause of these inconsistencies are not known, however individual species differences on how the animal responds to the parasites might be among the differentiating factors as previously described (Bandi and Saikumar, 2013). Furthermore, the self-limiting nature of the disease observed in baboon and red colobus monkeys cannot rule out the possibility of missing past events. The self-recovery implies that the disease in the two primate species may not immediately warrant medical interventions. The intervention may be necessary only if the

condition persist and becomes life-threatening especially for Zanzibar red colobus monkeys where loss of even a few individual is critical for the maintenance of the species which is threatened and only

endemic to Zanzibar. Lastly, zoonotic nature and the potential of the disease to cause mortalities in primates justify a closer monitoring in areas with higher human and animal interactions.

ACKNOWLEDGEMENTS

The assistance of Mr. Zemu Mbilu in the course of sample processing, Saadani National Assistant Conservation Commissioner, Ms. Grace Lobora, Conservation Assistant – Wildlife Management, Ms. Hellen Mihayo and Conservation Rangers, Mr. Tumaini Magessa. Also the assistance of Mr. Kombo Rajabu from Serengeti National Parks, The

Revolutionary Government of Zanzibar (Ministry of Agriculture, Natural Resources, Livestock and Fisheries, the Directorate for Veterinary Services) and Jozani-Chwaka Bay National Park Management specifically Dr. Yusuph Hajji, Dr. Abbas Mzee, Dr. Othman, Mr. Ali Mwinyi, Mr. Mzee Hamisi, Ms. Sofie Kimla and her husband as well as Dr. Alex are equally thanked

REFERENCES

- Bandi KM, Saikumar C. Sarcoptic mange: a zoonotic ectoparasitic skin disease. *J Clin Diagn Res*, 7: 156-157, 2013.
- Bernstein JA, Didier PJ. Nonhuman primate dermatology: a literature review. *Vet Dermatol*, 20: 145-156, 2009.
- Hill KR. Non-specific factors in the epidemiology of yaws. *Bull World Health Organ*, 8: 17, 1953.
- Kalema-Zikusoka G, Kock RA, Macfie EJ. Scabies in free-ranging mountain gorillas (*Gorilla beringei beringei*) in Bwindi Impenetrable National Park, Uganda. *The Veterinary record*, 150: 12-15, 2002.
- Mackenstedt U, Jenkins D, Romig T. The role of wildlife in the transmission of parasitic zoonoses in peri-urban and urban areas. *Int J Parasitol Parasites Wildl*, 4: 71-79, 2015.
- Mittermeier RA, Wallis J, Rylands AB, *et al*. Primates in peril: the world's 25 most endangered primates 2008–2010. *Primate Conserv*, 24: 1-58, 2009.
- Pence DB, Ueckermann E. Sarcoptic mange in wildlife. *Rev Sci Tech*, 21: 385-398, 2002.
- Sokolova TV, Radchenko MI, Lange AB. [The seasonality of scabies morbidity and the fertility of the itch mite *Sarcoptes scabiei* de Geer as an index of the activity of a population of the causative agent]. *Vestn Dermatol Venerol*: 12-15, 1989